

This is the peer reviewed version of the following article: Burrows, A. M., Waller, B. M., & Micheletta, J. (2016). Mimetic muscles in a despotic macaque (*Macaca mulatta*) differ from those in a closely related tolerant macaque (*M. nigra*). *The Anatomical Record*, which has been published in final form at <http://doi.org/10.1002/ar.23393>. This article may be used for non-commercial purposes in accordance with Wiley Terms and Conditions for Self-Archiving.

Mimetic muscles in a despotic macaque (*Macaca mulatta*) differ from those in a closely related tolerant macaque (*M. nigra*)

Anne M. Burrows* ^{1,2}, Bridget M. Waller³, Jérôme Micheletta³

¹ Department of Physical Therapy, Duquesne University, USA ²
Department of Anthropology, University of Pittsburgh, USA ³
Department of Psychology, University of Portsmouth, UK

* -- Corresponding Author: Anne M. Burrows, Dept. of Physical Therapy, 600 Forbes Ave., Duquesne University, Pittsburgh, PA 15282; phone: 412.396.5543; fax: 412.396.4399; email: burrows@duq.edu

Abstract:

Facial displays (or expressions) are a primary means of visual communication among conspecifics in many mammalian orders. Macaques are an ideal model among primates for investigating the co-evolution of facial musculature, facial displays, and social group size/behavior under the umbrella of “ecomorphology”. While all macaque species share some social behaviors, dietary, and ecological parameters, they display a range of social dominance styles from despotic to tolerant. A previous study found a larger repertoire of facial displays in tolerant macaque species relative to despotic species. The present study was designed to further explore this finding by comparing the gross morphological features of mimetic muscles between the Sulawesi macaque (*Macaca nigra*), a tolerant species, and the rhesus macaque (*M. mulatta*), a despotic species. Five adult *M. nigra* heads were dissected and mimetic musculature was compared to those from *M. mulatta*. Results showed that there was general similarity in muscle presence/absence between the species as well as muscle form except for musculature around the external ear. *M. mulatta* had more musculature around the external ear than *M. nigra*. In addition, *M. nigra* lacked a zygomaticus minor while *M. mulatta* is reported to have one. These morphological differences match behavioural observations documenting a limited range of ear movements used by *M. nigra* during facial displays. Future studies focusing on a wider phylogenetic range of macaques with varying dominance styles may further elucidate the roles of phylogeny, ecology, and social variables in the evolution of mimetic muscles within *Macaca*

Keywords: facial expression, evolution, face, ecomorphology, socioecology

INTRODUCTION

Macaques (Primates: Haplorrhini: Cercopithecidae: Papioninae) are the most successful and ubiquitous extant primate, next to humans (Thierry, 2007). There are in excess of 20 species of *Macaca* and their geographic range is remarkably extensive, including northern Africa, southern Europe, Southeast Asia, and mountainous regions of Japan (Fooden & Lanyon, 1989; Groves, 2001; Li et al., 2009). While most macaque species are found in Asia, macaques inhabit climates as diverse as semi-desert, mountains, evergreen forests, and tropical forests (Fooden, 1982). Macaques as a group are one of the most frequently used primates in biomedical modelling of human pathology and they are sometimes used as models of human social evolution and social behaviour. Thus, our understanding of the interplay among macaque evolution, social behavior, and ecomorphological variables is important to many aspects of the human lifecycle and human social evolution.

Macaques are a monophyletic group (Delson, 1980; Li et al., 2009). Their evolutionary story is not complete but it is generally agreed that the first macaques diverged from other papionins (the baboons, drills, mandrills, geladas, and mangabeys) around 9MYA (Raaum et al., 2005). The earliest macaque fossils (dated to around 5 MYA) suggest that they evolved in northern or eastern Africa, eventually moving into Eurasia and the Near East. There is evidence that this deployment occurred in three successive, distinct waves with *Macaca sylvanus* (the Barbary macaque of northern Africa) representing the most ancient member (Delson, 1980; Jablonski, 2002; Li et al., 2009). Three major extant lineages are now recognized: a “silena” lineage (which includes *M. nigra*) which is considered to be the most ancient, a “sinica” lineage, and a “fascicularis” lineage (which includes *M. mulatta*).

Macaques share few apomorphies. Like all cercopithecines, they are semi-terrestrial and have cheek pouches. One of the defining characteristics of macaques is the unique presence of maxillary sinuses among the cercopithecoids (Rae et al., 2002; Thierry et al., 2004). Ecological preferences are not linked overtly to phylogeny. Some macaque species are uniquely and remarkably successful in urban settings, thriving alongside humans. While macaques are conceptualized as frugivorous, many species depend upon other food items such as leaves, seeds, invertebrates, and opportunistically feed on small vertebrates. These food choices can, in turn, be influenced by group size (Thierry, 2007).

Group sizes among species vary enormously and can vary within species seasonally. In unprovisioned groups, mean group sizes typically fall somewhere within the 15-50 individual range but group sizes of 70-90 are not uncommon in *M. mulatta*, *M. fuscata*, and *M. sylvanus* (Fooden, 2000; Yamagiwa and Hill, 1998; Ménard, 2004). All species form multi-male/multi-female groups with female philopatry (i.e., females stay with their natal group), dominance along the matriline, and males typically disperse.

In contrast to these similarities in basic socio-demographic characteristics, macaques differ widely in their pattern of aggression, affiliation, dominance and nepotism (Thierry, 2007). These differences can be used to rank the different species on a 4-grade scale of increasing social tolerance

(Table 1). Species from grade 1 are termed “despotic” and include the rhesus macaque (*Macaca mulatta*). They are characterized by strong constraints imposed by dominance and kinship on their social interactions (Thierry, 2007). Low-ranking individuals explicitly signal their submissive social status when approached by higher-ranking individuals by using a formal signal of submission – the *silent bared-teeth* facial display (de Waal & Luttrell, 1985). These species are characterized by low rates of counter-aggression during dominance interactions so that subjects of aggression, typically low-ranking individuals, flee or submit. The outcome and progression of aggressive encounters rarely vary and are typically certain. Conflicts are frequent and are directed from dominant to subordinate with low rates of post-conflict reconciliation (Petit et al., 1997; Thierry, 1985). Stereotypical facial displays play a big role in social interactions among individuals of despotic species (e.g., Parr et al., 2010; Dobson, 2012).

In species from grade 4 (which includes crested macaques, *M. nigra*), social relationships are more relaxed. There is a high degree of social uncertainty and the outcomes and progressions of agonistic encounters vary (Duboscq et al., 2013a; Thierry, 1985). Fights are frequent but often of low intensity and many of the conflicts involve peaceful interventions by third parties (Petit & Thierry, 1994a), followed by reconciliation (Duboscq et al., 2014; Petit & Thierry, 1994b; Thierry et al., 2008). In tolerant species, the silent bared-teeth display is not a formal signal of subordination but instead, it is often followed by affiliative interactions (Duboscq et al., 2013).

The social networks of tolerant macaques are characterised by a higher complexity than the despotic species (Sueur et al. 2011). Notably, tolerant macaque species have a higher number of social relationships between different individuals. High-ranking individuals are well connected to the rest of the group and interactions are only weakly constrained by dominance and kinship, leading to extended networks of social partners (Sueur et al., 2011).

The high degree of social uncertainty in more tolerant macaques was linked to a higher repertoire of facial displays than in despotic species by Dobson (2012). Macaques routinely use facial expressions/displays in their social encounters (de Waal & Luttrell, 1989; Preuschoft, 1995; Preuschoft & van Schaik, 2000; Parr et al., 2010). With a more open-ended set of possible progressions and outcomes in these tolerant macaque species, an expanded repertoire of facial displays may be useful in protest, counter-attack, and conciliation during and following agonistic encounters.

The present study expands upon the findings from Dobson (2012) by investigating the facial musculature of the tolerant *M. nigra* compared to a representative of the despotic group, *M. mulatta*. Number of muscles is not always a good predictor of facial display repertoire within primates (Burrows, 2008). Repertoire also depends upon muscle physiology, neural control (via the facial nerve as well as facial nerve nuclei), muscle attachments, dentition, etc. However, the present study examines muscle morphology as a first step to conceptualizing morphological aspects of facial displays.

MATERIALS & METHODS

Heads from cadavers of five Sulawesi crested macaques (*M. nigra*) were used in the current study (two males, two females, one unknown sex). All cadavers were obtained from Marwell Zoo and Chester Zoo (UK) and shipped to the National Museums of Scotland for curation following death. All specimens were frozen at the museum and held for dissection. Dissections were carried out at the National Museums of Scotland.

All cadavers were thawed at room temperature overnight. Three specimens had already had the head disarticulated from the cervical spine by museum staff prior to dissection. In all specimens, incisions were made around the neck to reflect the facial skin & scalp from the underlying structures. As in previous studies (e.g., Burrows et al., 2006, 2009, 2011) some of the mimetic musculature was removed with the skin flaps and some was left attached to the skull.

Mimetic muscles were identified using previous works on both *M. nigra* and *M. mulatta* (Huber, 1933; Seiler, 1971, 1974; Burrows et al., 2009). Muscle presence/absence, morphology, and attachments were noted. Since some of the heads had already been disarticulated from the cervical part of the spine, some caudal muscle attachments were unavailable (e.g., the occipitalis muscle, the platysma muscle). Comparisons between the mimetic musculature of *M. nigra* and *M. mulatta* were carried out using results from previous studies on *M. mulatta* (Huber, 1933; Burrows et al., 2009).

RESULTS

Attachments of mimetic muscles found in the present study are described in Table 1. Because of the overall similarity between mimetic muscles of *M. nigra* from the present study and those of *M. mulatta* (see Seiler, 1974; Burrows et al., 2009), major differences between the two species are highlighted here in Table 1 and Figure 1. Table 2 shows muscles that were present/absent in *M. nigra* and *M. mulatta* along with functions and corresponding video frame numbers showing the function (found in Supplementary Material).

Musculature of the scalp

Both a robust occipitalis muscle and frontalis muscle were located in all specimens of *M. nigra* with no differences noted compared to *M. mulatta*.

Musculature of the pinna

While five specimens of *M. nigra* were used in the present study, only three specimens had the external ear intact, so all reports here are with reference to three specimens. Many differences were found between the musculature of *M. nigra* and *M. mulatta* (see Tables 1 and 2 & Figure 1). A

previous study on one specimen of *M. nigra* (Seiler, 1971) did not focus on musculature of the pinna.

All specimens of *M. nigra* in the present study had a well-developed orbitoauricularis muscle, similar to that of *M. mulatta* (Burrows et al., 2009). Previous dissections of *M. mulatta* described a well-developed, two-headed posterior auricularis muscle (Burrows et al., 2009) or a single-headed muscle (e.g., Seiler, 1974) but *M. nigra* in the present study had a much smaller, single-headed posterior auricularis muscle that was present in two out of three specimens.

The superior auricularis muscle was found in two out of three *M. nigra* specimens but was morphologically unremarkable relative to that of *M. mulatta* (Seiler, 1974; Burrows et al., 2009).

The inferior auricularis muscle was present in one out of the three *M. nigra* specimens. This muscle was also variably present in *M. mulatta* (Burrows et al., 2009). Seiler (1974) found this muscle to be absent in *M. fuscata* but present in *M. mulatta*. The attachments in the present study on *M. nigra* were similar to the attachments for *M. mulatta* (Seiler, 1974; Burrows et al., 2009).

There was no anterior auricularis muscle located in specimens from the present study. Seiler (1974) reported this muscle in both *M. mulatta* and *M. fuscata* but Burrows et al. (2009) reported a variably present anterior auricularis (two specimens out of six) in *M. mulatta*.

Lastly, a distinct tragicus muscle was located in all specimens of *M. nigra*. This muscle was not documented in *M. mulatta* by Burrows et al. (2009). It was, however, located in *M. mulatta* and *M. fuscata* by Seiler (1974). Confounding this result, there was no antitragicus muscle found in the present study but it was reported as being present in *M. mulatta* (Seiler, 1974; Burrows et al., 2009).

Muscles of the orbital and superciliary regions

All specimens from the present study had a robust orbicularis oculi muscle with attachments as in *M. mulatta*. A robust corrugator supercilli muscle was also noted in all *M. nigra* specimens with attachments similar to those of *M. mulatta*.

No depressor supercilli muscle was noted in the present study. Seiler (1971) reported the presence of this muscle in the single specimen of *M. nigra* (termed *Cynopithecus niger* therein). Depressor supercilli muscle was reported in a previous study of *M. mulatta* (Burrows et al., 2009). Both species of macaque have a procerus muscle with no variations in attachments noted but it appeared to be more gracile in *M. nigra* relative to *M. mulatta*.

Muscles of the nasal and upper lip regions

All specimens had a robust orbicularis oris muscle with form and attachments similar to those of *M. mulatta*. No specimen of *M. nigra* had a risorius muscle, matching previous observations from *M. mulatta* (Burrows et al., 2009). Seiler (1971) did not report a risorius muscle in his single specimen of *M. nigra*.

A depressor septi muscle was noted in *M. nigra* with form and attachments similar to

those of *M. mulatta*. This muscle was also found in the single specimen from Seiler (1971).

There was a robust levator labii superioris alaeque nasi muscle (LLSAN) found in the present study with attachments similar to those in *M. mulatta* (Burrows et al., 2009) and it was reported by Seiler (1971) as well.

The levator labii superioris muscle was present in specimens from the present study and was reported by Seiler (1971). Form and attachment were similar to those of *M. mulatta*.

Zygomaticus major muscle was found in the present study with distinct differences relative to *M. mulatta*. Burrows et al. (2009) reported that the zygomaticus major muscle in *M. mulatta* regularly occurred as a muscle with a single origin near the zygomatic arch that split into two heads shortly thereafter. Both heads attached near the modiolar region of the mouth. In *M. nigra* from the present study, the zygomaticus major muscle existed as one single head from the zygomatic arch to the modiolar region of the mouth. However, Seiler (1971) described a two-headed zygomaticus major muscle in his single *M. nigra* specimen. Importantly, the *M. nigra* specimens from the present study never showed a zygomaticus minor muscle (see Figure 1) while Seiler (1971) reported the presence of a zygomaticus minor muscle. Burrows et al. (2009) reported routine presence of the zygomaticus minor muscle in *M. mulatta*.

The caninus muscle was an exceptionally large, robust muscle found in the present study as well as by Seiler (1971). While the attachments of this muscle did not differ from those of *M. mulatta* (Burrows et al., 2009), the caninus muscle in *M. nigra* was much larger.

Muscles of the lower lip and mental regions

The platysma muscle found in the present study did not vary from the form seen in *M. mulatta*. Seiler (1971) did not report on this muscle. Because some of the heads had been disarticulated from the cervical part of the spine in specimens from the present study, attachments cannot be discerned with certainty but it is unlikely that they differ from those of *M. mulatta*. As in *M. mulatta*, the platysma muscle of *M. nigra* from the present study attached partially into the walls of the cheek pouch, potentially helping to expel contents of the pouch.

The depressor anguli oris muscle of *M. nigra* was not different from *M. mulatta* (Burrows et al., 2009). Neither the mentalis muscle nor the depressor labii inferioris muscle differed from the arrangement in *M. mulatta*. Seiler (1971) did not report on any of these muscles.

DISCUSSION

The present study documented 20 mimetic muscles in *Macaca nigra* cadavers. Seiler (1971) found the same muscles plus a zygomaticus minor and a depressor supercilli muscle. Seiler did not, though, report on any muscles of the pinna so it is not possible to compare results. Given the sample

size differences, it is not surprising that these results vary. Zygomaticus minor is a muscle that varies within human (Standring, 2015) so it is not surprising to see if vary among other primate species. This muscle has been found in gibbons and siamangs (Burrows et al., 2011; Diogo et al., 2012), chimpanzees (Burrows et al., 2006; Diogo et al., 2013a), rhesus macaques (Burrows et al., 2009), and many other primate species (Diogo et al., 2009; Diogo et al., 2013b; Diogo & Wood, 2011). Swindler describes a sheet-like zygomaticus mass for *Papio*.

While depressor supercilli was not found in the present study it is reported to occur in *M. mulatta* (Burrows et al., 2009) and in a wide range of primates (Diogo & Wood, 2011). Seiler (1971) reported it.

Relative to *M. mulatta* (Burrows et al., 2009), *M. nigra* from the present study were missing the zygomaticus minor muscle, the depressor supercilli muscle, an antitragus muscle, and a levator anguli oris muscle (reported in Seiler, 1971 as the “cuspidator oris muscle”). While it’s possible that an expanded caninus muscle, found in the present study, “crowded out” the visibility of the levator anguli oris muscle in the present study, it’s also possible that this muscle varies.

The most obvious facial region where *M. nigra* varies from *M. mulatta* is at the external ear, the pinna. Seiler (1974) and Burrows et al. (2009) documented robust posterior auricularis and superior auricularis muscles in *M. mulatta* as well as variably present anterior auricularis and inferior auricularis muscles. Both a tragus muscle and an antitragus muscle were found in *M. mulatta* as well. *M. nigra* from the present study had poorly developed but present posterior auricularis and superior auricularis muscles, a similar inferior auricularis muscle, but an absent anterior auricularis muscle and antitragus muscle.

These morphological differences correspond to behavioral observations of wild and captive populations (Thierry et al., 2000, Micheletta et al., 2013). Although *M. nigra* seems to be able to produce the same movements as *M. mulatta*, in *M. nigra*, most ear movements seem to involve the inferior auricularis, which leads to the ear being flattened against the back of the head. This particular facial movement is an integral component of a number of facial expressions across contexts in this species (e.g. silent bared-teeth, lipsmack and jaw movement: Thierry et al., 2000) although the effect of this visual component on receivers’ behavior remains largely unknown (but see Micheletta et al. 2013).

According to the social complexity hypothesis for communication complexity, the complexity of a social system drives the evolution of communication within this system (Freeberg et al., 2012). Tolerant societies are presumably more complex given the wider range and diversity of interactions characterizing their social system and therefore, should display a more complex communication system. Using a published behavioral repertoire, Dobson (2012) documented a greater number of facial display in tolerant macaques (such as *M. nigra*) relative to despotic species (such as *M. mulatta*), supporting the prediction from the social complexity hypothesis. However, this same prediction is not supported by the anatomical data presented here. In a previous study (Burrows et al., 2009), *M. mulatta* had 24 individual mimetic muscles compared to the 20 documented here for

M. nigra.

Since facial displays are composite signals made up of a number of distinctive facial movements, it would seem intuitive that having more muscles translates into more complex and/or numerous facial expressions. However, the number of muscles is not always a good predictor of facial display repertoire within primates (Burrows, 2008). In addition to a number of physiological and neurological factors, repertoire size depends on the combination of muscles activated to produce facial expressions. Crested macaques' facial expressions are highly blended and graded, making it difficult to accurately quantify the size of their repertoire.

Ultimately, the development of a Facial Action Coding System (FACS) dedicated to crested macaques, or the validation of the rhesus macaque FACS (maqFACS, Parr et al. 2010) for crested macaques (see Julle-Danière et al., 2015 for a validation of maqFACS for Barbary macaques) should allow us to conduct more detailed and accurate comparison of the facial expressions between these species.

ACKNOWLEDGEMENTS

This work was funded by a British Academy/Leverhulme Small Research Grant to JM, BMW and AMB. We thank Andrew Kitchener and the National Museums of Scotland for access to specimens, Églantine Jule-Danières, Caroline Gass and Lola Reverchont-Billot for their help. The authors also thank the two anonymous reviewers and associate editor. Their comments greatly improved the quality of this submission.

REFERENCES

- Burrows AM. 2008. The facial expression musculature in primates and its evolutionary significance. *Bioessays* 30: 212-225.
- Burrows AM, Diogo R, Waller BM, Bonar CJ, Liebal K. 2011. Evolution of the muscles of facial expression in a monogamous ape: Evaluating the relative influences of ecological and phylogenetic factors in hylobatids. *Anat Rec* 294: 645-663.
- Burrows AM, Parr LA, Durham EL, Matthews LC, Smith TD. 2014. Human faces are slower than chimpanzee faces. *PLoS ONE* 9(10): e110523. doi:10.1371/journal.pone.0110523
- Burrows AM, Smith TD. 2003. Muscles of facial expression in *Otolemur*, with a comparison to Lemuroidea. *Anat Rec* 274: 827-836.
- Burrows AM, Waller BM, Parr LA. 2009. Facial musculature in the rhesus macaque (*Macaca mulatta*): evolutionary and functional contexts with comparisons to chimpanzees and humans. *J Anat* 215: 320-334.

- Burrows AM, Waller BM, Parr LA, Bonar CJ. 2006. Muscles of facial expression in the chimpanzee (*Pan troglodytes*): descriptive, comparative and phylogenetic contexts. *J Anat* 208: 153-167.
- Delson E. 1980. Fossil macaques, phyletic relationships and a scenario of deployment. In: Lindburg DG, editor. *The Macaques: Studies in Ecology, Behavior, and Evolution*. New York: van Nostrand Rheinhold. p 10-30.
- de Waal FBM, Luttrell LM. 1985. The formal hierarchy of rhesus monkeys: an investigation of the bared-teeth display. *Am J Primatol* 9: 73-85.
- de Waal FBM, Luttrell LM. 1989. Toward a comparative socioecology of the genus *Macaca*: different dominance styles in rhesus and stumptail monkeys. *Am J Primatol* 19: 83-109.
- Diogo R, Potau JM, Pastor JF, de Paz FJ, Ferrero EM, Bello G, Barbosa M, Aziz MA, Burrows AM, Arias-Martorell J, Wood BA. 2012. *Photographic and Descriptive Musculoskeletal Atlas of Gibbons and Siamangs (Hylobates)*. Boca Raton, FL: CRC Press.
- Diogo R, Potau JM, Pastor JF, de Paz FJ, Ferrero EM, Bello G, Barbosa M, Aziz MA, Burrows AM, Arias-Martorell J, Wood BA. 2013a. *Photographic and Descriptive Musculoskeletal Atlas of Chimpanzees*. Boca Raton, FL: CRC Press.
- Diogo R, Potau JM, Pastor JF, de Paz FJ, Ferrero EM, Bello G, Barbosa M, Aziz MA, Arias-Martorell J, Wood BA. 2013b. *Photographic and Descriptive Musculoskeletal Atlas of Orangutans*. Boca Raton, FL: CRC Press.
- Diogo R, Wood BA. 2011. Soft-tissue anatomy of the primates: phylogenetic analyses based on the muscles of the head, neck, pectoral region and upper limb, with notes on the evolution of these muscles. *J Anat* 219: 273-359.
- Diogo R, Wood BA, Aziz MA, Burrows A. 2009. On the origin, homologies and evolution of primate facial muscles, with a particular focus on hominoids and a suggested unifying nomenclature for the facial muscles of the Mammalia. *J Anat* 215: 300-319.
- Dobson SD. 2012. Coevolution of facial expression and social tolerance in macaques. *Am J Primatol* 74: 229-235.
- Duboscq J, Agil M, Engelhardt A, Thierry B. 2014. The function of postconflict interactions: new prospects from the study of a tolerant species of primate. *Anim Behav* 87: 107–120.
- Duboscq J, Micheletta J, Agil M, Hodges K, Thierry B, Engelhardt A. 2013. Social tolerance in wild female crested macaques (*Macaca nigra*) in Tangkoko-Batuangus Natur Reserve, Sulawesi, Indonesia. 2013. *Am J Primatol* 75: 361-375.
- Fooden J. 1982. Ecogeographic segregation of macaque species. *Primates* 23: 574-579. Fooden J.

2000. Systematic review of the rhesus macaque *Macaca mulatta* (Zimmermann, 1780). *Fieldiana Zool* 96: 1-179.
- Fooden J, Lanyon SM. 1989. Blood protein allele frequencies and phylogenetic relationships in *Macaca*: A review. *Am J Primatol* 17: 209–241.
- Freeberg T M, Dunbar R I M, Ord TJ. 2012. Social complexity as a proximate and ultimate factor in communicative complexity. *Phil Trans Royal Soc B* 367: 1785–1801.
- Groves C. 2001. *Primate Taxonomy*. Washington, D.C. : Smithsonian Institution Press.
- Huber E. 1931. *Evolution of Facial Musculature and Facial Expression*. Baltimore: The Johns Hopkins Press.
- Jablonski NG. 2002. Fossil Old World monkey: the late Neogene radiation. In: Hartwig WC, editor. *The Primate Fossil Record*. Cambridge: Cambridge University Press. p 255-300.
- Julle-Danière E, Micheletta J, Whitehouse J, Joly M, Gass C, Burrows AM, Waller BM. 2015. MaqFACS (Macaque Facial Action Coding System) can be used to document facial movements in Barbary macaques (*Macaca sylvanus*). *PeerJ*, 3, e1248. <http://doi.org/10.7717/peerj.1248>.
- Li J, Han K, Xing J, Kim H-S, Rogers J, Ryder OA, Disotell T, Yue B, Batzer MA. 2009. Phylogeny of the macaques (Cercopithecidae: *Macaca*) based on Alu elements. *Gene* 448: 242-249.
- Ménard N. 2004. Do ecological factors explain variation in social organization? In: Thierry B, Singh M, Kaumanns W, editors. *Macaque Societies: A Model for the Study of Social Organization*. Cambridge: Cambridge University Press. p 237-262.
- Micheletta J, Engelhardt A, Matthews L, Agil M, Waller BM. 2013. Multicomponent and multimodal lipsmacking in crested macaques (*Macaca nigra*). *Am J Primatol* 75: 763– 773.
- Parr LA, Waller BM, Burrows AM, Gothard KM, Vick SJ. 2010. MaqFACS: A muscle based facial movement coding system for the rhesus macaque. *Am J Phys Anthropol* 143: 433-445.
- Petit O, Abegg C, Thierry B. 1997. A comparative study of aggression and conciliation in three cercopithecine monkeys (*Macaca fuscata*, *Macaca nigra*, and *Papio papio*). *Behaviour* 134: 415-431.
- Petit O, Thierry B. 1994a. Aggressive and peaceful interventions in conflicts in Tonkean macaques. *Anim Behav* 48: 1427–1436.
- Petit O, Thierry B. 1994b. Reconciliation in a group of black macaques, *Macaca nigra*. *Dodo* 30: 89-95.
- Preuschoft S. 1995. *Laughter and Smiling in Macaques: An Evolutionary Perspective*. Utrecht: Tessel

Offset B.V.

- Preuschoft S, van Schaik CP. 2000. Dominance and communication. Conflict management in various social settings. In: Aureli F, de Waal FBM, editors. *Natural Conflict Resolution*. Hillsdale, NJ: Erlbaum. p 171-189.
- Raaum RL, Sterner KN, Noviello CM, Stewart CB, Disotell TR. 2005. Catarrhine primate divergence dates estimated from complete mitochondrial genomes: concordance with fossil and nuclear DNA evidence. *J Hum Evol* 48: 237–257.
- Rae TC, Koppe T, Spoor F, Benefit B, McCrossin M. 2002. Ancestral loss of the maxillary sinus in Old World monkeys and independent acquisition in *Macaca*. *Am J Phys Anthropol* 117: 293-296.
- Scheider L, Liebal K, Ona L, Burrows A, Waller B. 2014. A comparison of facial expression properties in five hylobatid species. *Am J Primatol* 76: 618-628.
- Seiler R. 1971. Facial musculature and its effect on the facial skeleton in catarrhine primates. *Gegenbaurs Morphol Jahrb* 116: 347-376.
- Seiler R. 1974. Die Muskeln des äußeren Ohres und ihre Funktion bei Menschen, Schimpansen und Makaken. *Gegenbaurs Morphol Jahrb* 120: 78-122.
- Standring S. 2015. *Gray's Anatomy*, 41st edition. London: Elsevier.
- Sueur C, Petit O, De Marco A, Jacobs A, Watanabe K, Thierry B. 2011. A comparative network analysis of social style in macaques. *Anim Behav* 82: 845-852.
- Thierry B. 1985. Patterns of agonistic interactions in three species of macaque (*Macaca mulatta*, *M. fascicularis*, *M. tonkeana*). *Aggress Behav* 11: 223-233.
- Thierry B. 2007. The macaques: a double-layered social organization. In: Campbell CJ, Fuentes A, MacKinnon KC, Panger M, Bearder SK, editors. *Primates in Perspective*. New York: Oxford University Press. p 224-239.
- Thierry B, Bynum EL, Baker SC, Kinnaird MF, Matsumura S, Muroyama Y, O'Brien TG, Petit O, Watanabe K. 2000. The social repertoire of Sulawesi macaques. *Prim Res* 16: 203–226.
- Thierry B, Singh M, Kaumanns W. 2004. Why macaque societies? In: Thierry B, Singh M, Kaumanns W, editors. *Macaque Societies: A Model for the Study of Social Organization*. Cambridge: Cambridge University Press. p 3-10.
- Thierry B, Aureli F, Nunn CL, Petit O, Abegg C, de Waal FBM. 2008. A comparative study of conflict resolution in macaques: insights into the nature of trait covariation. *Anim Behav* 75: 847-860.

Vick SJ, Waller BM, Parr LA, Pasqualini MCS, Bard KA. 2007 A cross-species comparison of facial morphology and movement in humans and chimpanzees using the Facial Action Coding System (FACS). *J Nonverb Behav* 31: 1-20.

Waller B M, Par, L A, Gothard K M, Burrows A M, Fuglevand A J. 2008 Mapping the contribution of single muscles to facial movements in the rhesus macaque. *Physiol Behav* 95: 93– 100.

Yamagiwa J, Hill DA. 1998. Intraspecific variation in the social organization of Japanese macaques: past and present scope of field studies in natural habitats. *Primates* 39: 257-273.

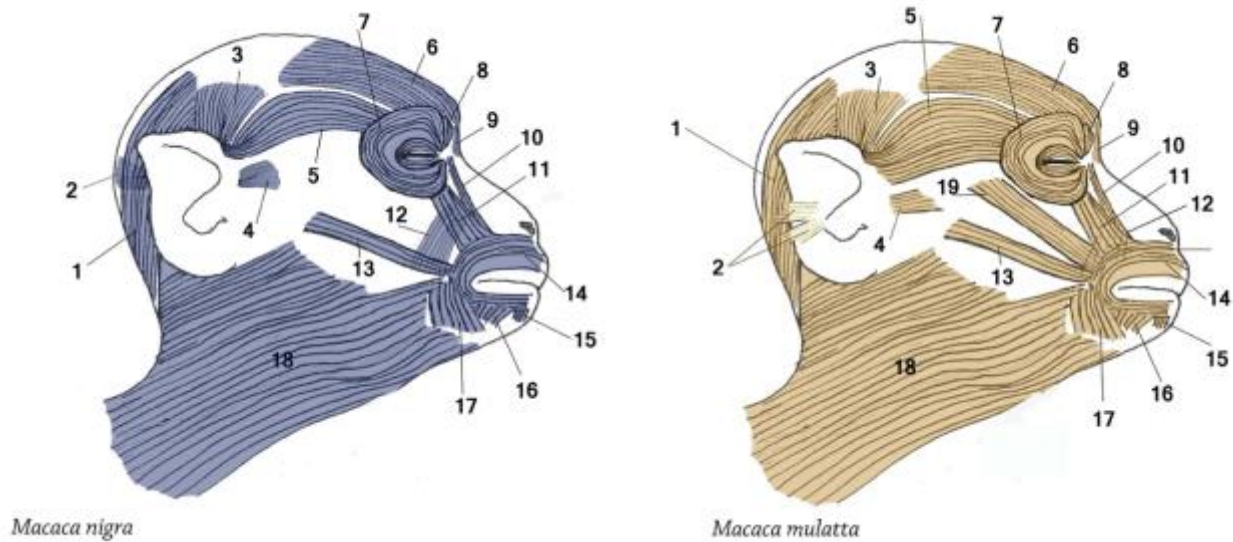


Figure 1: Left, in blue – Illustration of mimetic muscles found in the present study of *Macaca nigra*, with a comparison to, at right, in peach, *M. mulatta* (Burrows et al., 2009). 1 – occipitalis muscle; 2 – posterior auricularis muscle; 3 – superior auricularis muscle; 4 – anterior auricularis muscle; 5 – orbitoauricularis muscle; 6 – frontalis muscle; 7 – orbicularis oculi muscle; 8 – corrugator supercilli muscle; 9 – procerus muscle; 10 – levator labii superioris alaeque nasi muscle; 11 – levator labii superioris muscle; 12 – caninus muscle; 13 – zygomaticus major muscle; 14 – orbicularis oris muscle; 15 – mentalis muscle; 16 – depressor labii inferioris muscle; 17 – depressor anguli oris muscle; 18 – platysma muscle; 19 – zygomaticus minor muscle. Note that these images do not show the tragicus muscle (present in *M. nigra* but not in *M. mulatta*) or the antitragicus muscle (present in *M. mulatta* but not in *M. nigra*).

Table 1 – Mimetic muscles found in *Macaca nigra*, noted differences from *M. mulatta* indicated (see also Table 2 and Figure 1)

Muscle	Attachments	Differences
Platysma m.	Skin over lateral aspect of face; attached cranially as far as modiolus, the lower fibers of the orbicularis oris m. and depressor labii inferioris m.; attached into skin around cheek pouch and into skin of ventral neck	None noted
Orbitoauricularis m.	Cord-like fibers attached to the superolateral aspect of orbicularis oculi m. and to skin near superocranial region of pinna	Was variably present in rhesus macaque
Posterior Auricularis m.	Flat, thin fibers attached to the skin lateral to occipitalis m., caudal to the region of the pinna, and to the skin near the nuchal crest	Robust, two-headed muscle in rhesus macaque
Superior Auricularis m.	Scant, flat fibers attached to skin near the superior aspect of the pinna and to the fascia lateral to the frontalis m.	Robust, wide fibers in rhesus macaque
Inferior Auricularis m.	Gracile fibers superficial to platysma m.; attached to skin near inferior border of pinna and to the fascia at the superior region of the platysma m.	None noted
Tragicus m.	Small set of arcing fibers that attach to the helix and the tragus	None noted
Occipitalis m.	Flat muscle sheet attached to the fascia of the nuchal region and to the galea aponeurotica, just caudal to the coronal suture region	None noted
Frontalis m.	Flat muscle sheet attached to the galea aponeurotica near the coronal suture region and to fascia near superciliary region; mingles with fibers of the corrugator supercilli m. and procerus m.	None noted
Oribicularis Oculi m.	Sphincter-like fibers encircling orbital opening and horizontal fibers over eyelid; attached medially to medial palpebral region; attached to orbitoauricularis m.	None noted
Corrugator Supercilli m.	Robust set of vertical fibers deep to the orbicularis oculi m. attached to medial palpebral region and to skin at medial aspect of superciliary region	None noted
Procerus m.	Thin set of vertical fibers medial to the corrugator supercilli m.; attached to skin over nasal bone and to skin of perciliary region near the frontalis m.	None noted

Table 1 – Continued

Muscle	Attachments	Differences
Orbicularis Oris m.	Robust, sphincter-like fibers attached to the skin around the lips; upper fibers attached to levator labii m., caninus m., and LLSAN m.; lower fibers attached to platysma m., depressor labii inferioris m., and depressor anguli oris m.	None noted
LLSAN m.	Located medial to the levator labii m.; thin set of vertically-oriented fibers attached superiorly to the medial palpebral region and inferiorly to the upper fibers of the orbicularis oris m.	Much broader than found in rhesus macaque
Zygomaticus Major M.	Flat, wide sheet of fibers attached to the zygomatic arch and to the	In rhesus macaque, this muscle modiolar region splits into two heads near the modiolar attachment
Levator Labii m.	Flat, wide sheet of fibers attached to maxilla and nasal bones, the medial palpebral region, the skin over these regions, and into the lower fibers of the orbicularis oculi m.	None noted
Depressor Anguli Oris m.	Obliquely-oriented set of fibers that is attached to the upper fibers of the orbicularis oris m. and skin near the termination of the zygomaticus major m.; inferiorly, to the modiolar region and the cranial edge of the platysma m.	None noted
Depressor Septi m.	Attached superiorly to skin at the base of the medial border of the nares and, inferiorly, blending into upper fibers of orbicularis m.	None noted
Caninus m.	Excpetionally large, robust fibers attached superiorly to the region of the canine fossa of the maxilla and, inferiorly, into the modiolar	Much larger set of fibers than in rhesus macaque
Depressor Labii Inferioris m.	Flat sheet of fibers attached to the lower fibers of the orbicularis oris m. and into the skin around the lower fibers of the platysma m.	None noted
Mentalis m.	Triangular set of fibers attached to the lower fibers of the orbicularis oris m. and to the skin over the mental region of the mandible	None noted

Table 2 – Musculature present in Sulawesi macaque (*Macaca nigra*) and compared to rhesus macaque (*M. mulatta*) with movements and reference to corresponding video (in Supplementary Materials)

Muscle	<i>M. nigra</i>	<i>M. mulatta</i>	Movements	Video
Anterior auricularis m.	A	V (2/6)	-	-
Inferior auricularis m.	V (1/3)	P	Pull external ear inferiorly	53
Posterior auricularis m. ¹	V (2/3)	P	Pull external ear posteriorly	53
Superior auricularis m.	V (2/3)	V	Pulls external ear superiorly	123
Tragicus m.	P	P	Fine movement of external ear	-
Caninus m.	P	P	Elevate upper lip in region of canine	-
Corrugator supercilli m.	P	P	Draw skin of superciliary region inferomedially	-
Depressor anguli oris m.	P	P	Draw lateral portion of lower lip inferiorly	-
Depressor labii inferioris m.	P	P	Draw lower lip inferiorly	68
Depressor septi m.	P	P	Pull skin on the nasal septum inferiorly	-
Depressor supercilli m.	A	P	-	-
Frontalis m.	P	P	Elevates skin of the superciliary region	123
Levator labii superioris m.	P	P	Pulls upper lip superiorly	68
LLSAN m.	P	P	Elevates nasal ala	196
Mentalis m.	P	P	Pushes central portion of lower lip superiorly	54, 62
Occipitalis m.	P	P	Pulls skin of posterior part of scalp caudally	102
Orbicularis oculi m.	P	P	Squeezes eyelids shut	-
Orbicularis oris m.	P	P	Puckers lips and squeezes the lips shut	33, 53, 54
Orbitoauricularis m.	P	P	Pulls external ear toward orbit	-
Procerus m.	P	P	Pulls medial part of the skin over superciliary region inferiorly	14
Zygomaticus major m.	P	P	Pulls modiolar region of mouth caudally and superiorly	75, 102
Zygomaticus minor m.	A	P	-	-

Note: “P” —present; “V” —variable; “A” —absent; ¹ In *Macaca mulatta*, this muscle exists as a two-headed structure while in *M. nigra* it had only a single muscle head; facial movements corresponding to each muscles are based on behavioral observations of wild *M. nigra* (Micheletta et al. 2013) and intramuscular electrical stimulation in *M. mulatta* (Waller et al. 2008).